



# Cervical Kinematics After Fusion and Bryan Disc Arthroplasty

Rick C. Sasso, MD and Natalie M. Best, BS

**Introduction:** Disc arthroplasty has been shown to provide short-term clinical results that are comparable with those attained with traditional anterior cervical discectomy and fusion. One proposed benefit of arthroplasty is the ability to prevent or delay adjacent level operations by retaining motion at the target level and eliminating abnormal adjacent activity. This paper compares motion parameters for single-level anterior cervical discectomy and fusion and disc replacement patients at the index level and adjacent segments.

**Methods:** Radiographic data from patients enrolled in a prospective, randomized clinical trial were selected for kinematic assessment of cervical motion. All patients received either a single-level fusion with allograft and anterior cervical plate (Atlantis anterior cervical plate, n = 13) or a single-level artificial cervical disc (Bryan Cervical Disc prosthesis, n = 9) at either C5/C6 or C6/C7. Flexion, extension, and neutral lateral radiographs were obtained preoperatively, immediately postoperatively, and at regular intervals up to 24-month time points. Cervical vertebral bodies were tracked on the digital radiographs using quantitative motion analysis software (QMA, Medical Metrics) to calculate the functional spinal unit motion parameters including range of motion (ROM), translation, and center of rotation. If visible, the functional spinal unit parameters were obtained at the operative level, and also the level above and the level below.

**Results:** As expected, significantly ( $P < 0.006$  at 3, 6, 12, and 24 mo) more flexion/extension motion was retained in the disc replacement group than the plated group at the index level. The disc replacement group retained an average of 6.7 degrees at 24 months. In contrast, the average ROM in the fusion group was 2.0 degrees at the 3-month follow-up and gradually decreased to 0.6 degrees at 24 months. The flexion/extension ROM both above and below the operative level was not statistically different for the disc-replaced and fusion patients, however, mobility increased for both groups over time. The anterior/posterior translation that occurs with flexion/extension motion remained unchanged for the disc replacement group at the level above the target disc preoperatively and postoperatively. In

contrast, the translation increased for the level above the fusion. At the 6-month follow-up, the increase in translation was significantly greater for patients that were fused ( $P < 0.02$ ) than for patients that received a disc replacement. This change was not significant at 12 months.

**Discussion:** Previous studies have shown the Bryan disc to maintain mobility at the level of the prosthesis. The long-term clinical benefit of maintenance of motion is postulated to be the ability to delay or avoid adjacent level operations. This study reveals that there is no difference in flexion/extension ROM at the level above and below either a fusion or Bryan arthroplasty. There is, however, an increase in anterior/posterior translation at the cephalad adjacent level in patients with arthrodesis while the Bryan arthroplasty retains normal translation for the same amount of flexion/extension at the adjacent level.

**Conclusions:** The Bryan disc may delay adjacent level degeneration by preserving preoperative kinematics at adjacent levels.

**Key Words:** cervical spine, kinematics, arthroplasty, artificial disc, Bryan artificial disc replacement, fusion

(*J Spinal Disord Tech* 2007;00:000–000)

Anterior cervical discectomy and fusion (ACDF) is a proven intervention for patients with radiculopathy and myelopathy.<sup>1</sup> Because of limitations specific to this procedure, investigators have developed alternatives to fusion that attempt to address the kinematic and biomechanical issues inherent in fusing a cervical motion segment.

Adjacent segment degeneration requiring reoperation has been documented at a rate of 2.9% of patients per annum by Hilibrand et al.<sup>2</sup> Other reports have helped to shed light on the recurrence of neurologic symptoms and degenerative changes adjacent to fused cervical levels.<sup>2–5</sup> In patients undergoing cervical fusion, 25% will have new onset of symptoms within 10 years of that fusion.<sup>2</sup> Segments adjacent to a fusion are subjected to an increased range of motion (ROM) and increased intradiscal pressures<sup>6–9</sup>.

Intervertebral disc replacement is designed to preserve motion, avoid the limitations of fusion, and allow patients to quickly return to routine activities. It avoids the morbidity of bone graft harvest,<sup>10,11</sup> pseudarthrosis, complications of anterior cervical plating, and the side effects of cervical immobilization.

Received for publication June 16, 2006; accepted February 12, 2007.  
From the Indiana Spine Group and Indiana University School of Medicine, Indianapolis, IN.  
Reprints: Rick C. Sasso MD, Clinical Orthopaedic Surgery, Indiana University School of Medicine, Indiana Spine Group, 8402 Harcourt Rd., Suite 400, Indianapolis, IN 46260 (e-mail: rsasso@indianaspinegroup.com).

Copyright © 2007 by Lippincott Williams & Wilkins

Artificial disc implantation was first accomplished by Fernstrom<sup>12</sup> in 1966. In the late 1980s, Cummins et al<sup>13</sup> developed a metal-on-metal ball and socket cervical disc replacement comprised of 316L stainless steel. In May 2002, the Bryan cervical disc was the first cervical prosthesis to be implanted in the United States as part of a Food and Drug Administration (FDA) Investigation Device Exemption (IDE) study. The Bryan disc (Medtronic Sofamor Danek, Inc, Memphis, TN) is a one-piece, biarticulating, metal-on-polymer, unconstrained device with a fully variable instantaneous axis of rotation<sup>14,15</sup> and is the prosthesis used in this study.

One of the primary goals of cervical disc replacement is to reproduce normal kinematics after implantation. This includes the anterior-posterior translation routinely exhibited during flexion and extension. Motion studies have been conducted on human cadavers in the laboratory<sup>16,17</sup> but are limited by the mandatory artificial design of in vitro evaluation. The optimal method of assessing cervical kinematics is in a living human in vivo model. A recent study evaluated in vivo motion with the Bryan disc postoperatively as compared with preoperative movement.<sup>18</sup> The most valid study design, however, examines a prospective, randomized cohort of arthroplasty versus a control fusion population. The current study provides these data. This study aims to evaluate the ability of the Bryan disc device to maintain motion at the implanted level and also assess the motion at adjacent segments and compare this juxtalevel movement of arthroplasty to conventional arthrodesis.

**MATERIALS AND METHODS**

**Patient Population**

The first 22 consecutive patients enrolled in the Bryan cervical disc arthroplasty FDA IDE trial at one site are the subjects of this study. This is a prospective, randomized assessment of arthroplasty versus ACDF for the treatment of one-level cervical radiculopathy or myelopathy resistant to nonoperative treatment. All 22

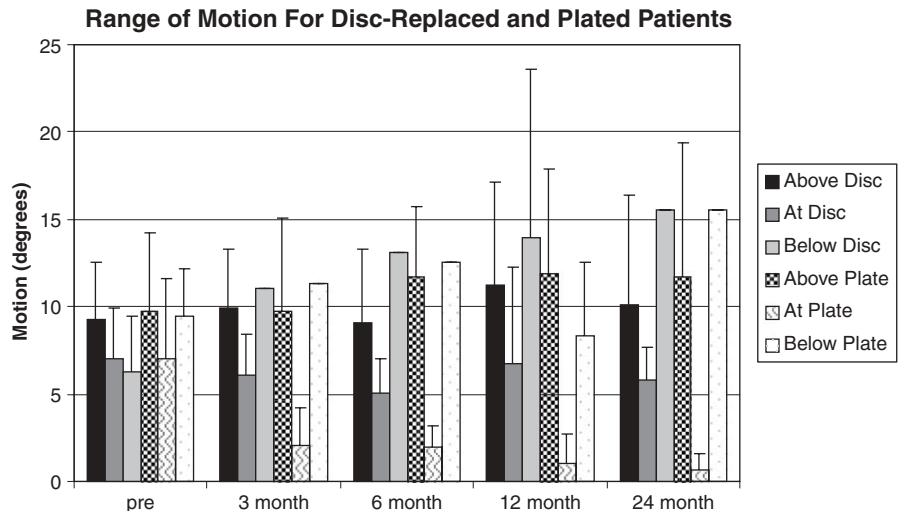
patients were operated by one surgeon from May 2002 to April 2003. They received either a single-level anterior cervical allograft/plate (Atlantis anterior cervical plate, n = 13) or an artificial cervical disc (Bryan Cervical Disc prosthesis, n = 9) at either C5/C6 or C6/C7. Twelve patients had their procedure at level C5/6 and 10 at C6/7. Thirteen patients (59.1%) were male. At the time of surgery, the patient population's ages ranged from 32 to 53 years with an average age of 42.4 ± 5.4 years.

**Evaluation of Kinematics**

Radiographic data from consecutive patients enrolled in a prospective, randomized clinical trial were selected for kinematic assessment of cervical motion. Flexion, extension, and neutral lateral radiographs were obtained preoperatively, immediately postoperatively and subsequent regular intervals up to 24 months. Cervical vertebral bodies were tracked on the digital radiographs using quantitative motion analysis (QMA) software (Medical Metrics; Houston, TX) to calculate the functional spinal unit motion parameters including ROM, translation, and center of rotation. This feature-tracking software has been used in a number of other studies.<sup>19-21</sup> If visible, the functional spinal unit parameters were obtained at the operative level, and also the level above and the level below. Translation was measured as displacement of the cephalad vertebral body along a line parallel to the cephalad endplate of the caudal vertebral body and measured as a percent of the length of that endplate.

**RESULTS**

Significantly ( $P < 0.006$  at 3, 6, 12, and 24 mo) more flexion/extension motion was retained in the disc replacement group compared with the plated group at the index level. The disc replacement group retained an average ROM of 6.7 degrees at 24 months. In contrast, the average ROM in the fusion group was 2.0 degrees at the 3-month follow-up and gradually decreased to 0.6 degrees at 24 months (Fig. 1).



**FIGURE 1.** Flexion/extension ROM for disc replaced and fusion patients; at the target level and also at the adjacent levels.

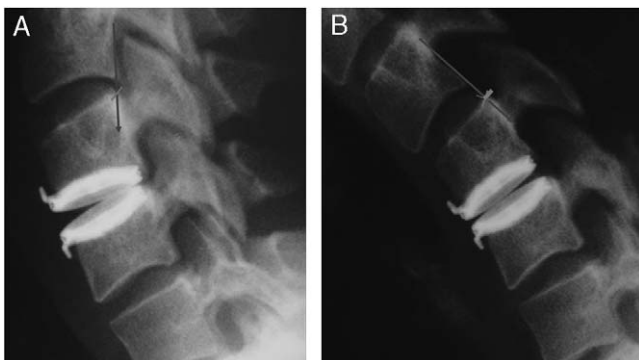
1 The flexion/extension ROM both above and below  
 2 the operative level was not statistically different for the  
 3 disc-replaced and fusion patients, however, mobility  
 4 increased for both groups over time (Fig. 1). The mean  
 5 anterior/posterior translation that occurs with flexion/  
 6 extension activities remained unchanged for the disc  
 7 replacement group (8.3% of endplate preoperatively,  
 8 8.4% at 6 mo, and 8.2% at 12 mo) for the level above  
 9 the disc (Fig. 2). In contrast, the translation increased  
 10 for the level above the fusion (8.5% of endplate preoperatively,  
 11 12.4% at 6 mo, and 11.0% at 12 mo). This increase  
 12 was dramatic for some fusion patients, but was not  
 13 uniformly noted (Fig. 3). At the 6-month follow-up, the  
 14 increase in translation was significantly greater for  
 15 patients that were fused ( $P < 0.02$ ) than for patients that  
 16 received a disc replacement. This change was not  
 17 significant at 12 months, perhaps owing to variability in  
 18 level of patient effort.

19  
 20  
 21 **DISCUSSION**

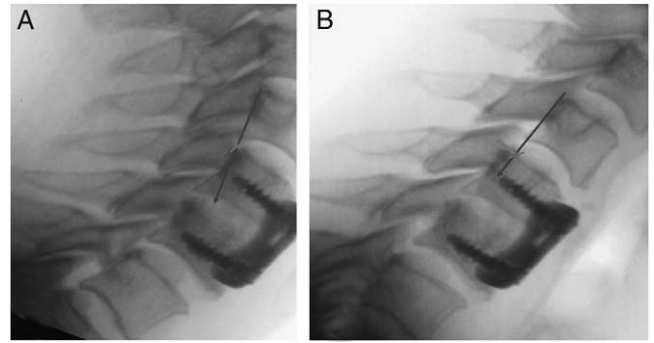
22 The long-term clinical benefit of maintaining motion  
 23 is postulated to be the delay or avoidance of adjacent  
 24 level degeneration. Disc replacement aims to preserve the  
 25 normal kinematics in the spine. The Bryan disc is one of  
 26 several arthroplasty systems currently being investigated  
 27 for use in the cervical spine. While each of these devices  
 28 has early outcome data, long-term studies assessing  
 29 adjacent segment degeneration are still pending.

30 Wigfield et al<sup>22</sup> reported favorable results on a 2-  
 31 year pilot study of the Prestige I Disc designed to address  
 32 the safety of the technique and to assess the stability of,  
 33 and motion allowed by, the device. They tried to target  
 34 patients most at risk for adjacent segment disease. Fifteen  
 35 patients were enrolled in the study. Motion was success-  
 36 fully preserved as radiographically demonstrated within  
 37 an appropriate physiologic range. Device stability was  
 38 concluded as no devices dislocated.

39 In a separate prospective nonrandomized study,  
 40 Wigfield et al<sup>9</sup> compared the effects of the Prestige Disc  
 41 and one-level anterior fusion on adjacent segment



56  
 57 **FIGURE 2.** A and B, Extension (A) and flexion (B) x-rays of the  
 58 disc space above a Bryan disc. The translation of the cephalad  
 59 vertebrae along the cephalad endplate of the caudal vertebrae  
 is relatively small.



72  
 73 **FIGURE 3.** A and B, Extension (A) and flexion (B) x-rays of the  
 74 disc space above a fusion. The translation of the cephalad  
 75 vertebrae along the cephalad endplate of the caudal vertebrae  
 is relatively large.

76  
 77  
 78  
 79 motion. No significant difference in adjacent segment  
 80 motion was measured between the 2 groups preopera-  
 81 tively. Postoperatively, there was a significant increase in  
 82 adjacent segment motion in the fusion group (mean 9  
 83 degree increase) compared with a slight reduction in  
 84 adjacent level motion noted in the disc group. In the  
 85 fusion group, adjacent segment motion increased 5% at 6  
 86 months and 15% at 1 year. Subgroup analysis showed  
 87 that increased motion occurs predominantly in normal  
 rather than degenerative adjacent discs.

88 In May 2002, the Bryan Cervical Disc was the first  
 89 cervical prosthesis to be implanted in the United States.  
 90 Early clinical studies have shown clinical success and  
 91 preserved motion at the implanted site.<sup>15,23-25</sup> Of  
 92 particular interest is whether the kinematics are preserved  
 93 at the operated segment and at adjacent segments. ROM  
 94 with the Bryan disc has been studied and has shown no  
 95 significant change in ROM at the operated level and at  
 96 adjacent levels postoperatively.<sup>19,20</sup> This study found  
 97 similar results. However, the strength of this study is  
 98 that it is a prospective, randomized comparison with the  
 99 conventional ACDF. One of the major criticisms of  
 100 ACDF is that it does not preserve the normal kinematics  
 101 of the spine and therefore may result in degeneration at  
 102 adjacent segments potentially requiring an additional  
 103 fusion.<sup>2-9</sup> This study did show preserved motion with the  
 104 Bryan disc as compared with ACDF. Flexion/extension  
 105 ROM was not determined to be significantly different  
 106 between populations at adjacent segments. However,  
 107 there was a significant difference in translation at the  
 108 level above the fusion after the surgery. To accomplish  
 109 similar flexion/extension ROM at the level above the  
 110 fusion, increased translation was found in the fusion  
 111 group. This increased translation at the adjacent level  
 112 may place excessive loads on the annulus and the facet  
 113 joints above a cervical fusion.

114 This study showed that the Bryan disc maintains  
 115 mobility at the level of the prosthesis, comparable with  
 116 the preoperative ranges. In addition, the study corrobo-

1 rates the findings of others and demonstrates that an  
 3 increase in anterior/posterior translation at the adjacent  
 5 level occurs in patients with arthrodesis.<sup>2-9</sup> It is therefore  
 7 postulated that the Bryan disc decreases risk for  
 degenerative translational motion. Further evaluation  
 needs to be done once long-term results have been  
 obtained.

9 **CONCLUSIONS**

11 Normal flexion/extension ROM continues out to 2  
 13 years after Bryan disc arthroplasty. The flexion/extension  
 15 ROM at adjacent levels to the Bryan disc and a fusion are  
 not different, but to allow this same motion above a  
 fusion-increased translation is demonstrated.

17 **REFERENCES**

19 1. Bohlman HH, Emery SE, Goodfellow DB, et al. Robinson anterior  
 21 cervical discectomy and arthrodesis for cervical radiculopathy.  
 23 Long-term follow-up of one hundred and twenty-two patients. *J*  
 25 *Bone Joint Surg Am.* 1993;75:1298-1307.  
 27 2. Hilibrand AS, Carlson GD, Palumbo MA, et al. Radiculopathy and  
 29 myelopathy at segments adjacent to the site of a previous anterior  
 31 cervical arthrodesis. *J Bone Joint Surg Am.* 1999;81:519-528.  
 33 3. Goffin J, Geusens E, Vantomme N, et al. Long-term follow-up after  
 35 interbody fusion of the cervical spine. *J Spinal Disord Tech.*  
 37 2004;17:79-85.  
 4. Goffin J, Van LJ, Van CF, et al. Long-term results after anterior  
 cervical fusion and osteosynthetic stabilization for fractures and/or  
 dislocations of the cervical spine. *J Spinal Disord Tech.*  
 1995;8:500-508.  
 5. Kulkarni V, Rajshekhar V, Raghuram L. Accelerated spondylotic  
 changes adjacent to the fused segment following central cervical  
 corpectomy: magnetic resonance imaging study evidence. *J Neuro-*  
*surg Spine.* 2004;100:2-6.  
 6. Eck JC, Humphreys SC, Lim TH, et al. Biomechanical study on the  
 effect of cervical spine fusion on adjacent-level intradiscal pressure  
 and segmental motion. *Spine.* 2002;27:2431-2434.  
 7. Fuller DA, Kirkpatrick JS, Emery SE, et al. A kinematic study o the  
 cervical spine before and after segmental arthrodesis. *Spine.*  
 1998;23:1649-1656.  
 8. Matsunaga S, Kabayama S, Yamamoto T. Strain on intervertebral  
 discs after anterior cervical decompression and fusion. *Spine.*  
 1999;24:670-675.

9. Wigfield C, Gill S, Nelson R. Influence of an artificial cervical joint  
 compared with fusion on adjacent-level motion in the treatment of  
 degenerative cervical disc disease. *J Neurosurg.* 2002;96:17-21. 41  
 10. Silber JS, Anderson DG, Daffner SD, et al. Donor site morbidity  
 after anterior iliac crest bone harvest for single-level anterior cervical  
 discectomy and fusion. *Spine.* 2003;28:134-139. 43  
 11. St John TA, Vaccaro AR, Sah AP, et al. Physical and monetary  
 costs associated with autogenous bone graft harvesting. *Am J*  
*Orthop.* 2003;32:18-23. 45  
 12. Fernstrom U. Arthroplasty with intercorporeal endoprosthesis in  
 herniated disc and in painful disc. *Acta Chir Scand Suppl.*  
 1966;357:154-159. 47  
 13. Cummins BH, Robertson JT, Gill SS. Surgical experience with an  
 implanted artificial cervical joint. *J Neurosurg.* 1998;88:943-948. 49  
 14. Anderson PA, Sasso RC, Rouleau JP, et al. The Bryan cervical disc:  
 wear properties and early clinical results. *The Spine J.*  
 2004;4:303S-309S. 51  
 15. Goffin J, Casey A, Kehr P, et al. Preliminary clinical experience with  
 the Bryan cervical disc prosthesis. *Neurosurg.* 2002;51:840-847. 55  
 16. DiAngelo DJ, Foley KT, Morrow BR, et al. In vitro biomechanics  
 of cervical disc arthroplasty with the ProDisc-C total disc implant.  
*Neurosurg Focus.* 2004;17:E7. 57  
 17. DiAngelo DJ, Roberston JT, Metcalf NH, et al. Biomechanical  
 testing of an artificial cervical joint and an anterior cervical plate. *J*  
*Spinal Disord Tech.* 2003;16:314-323. 59  
 18. Pickett GE, Rouleau JP, Duggal N. Kinematic analysis of the  
 cervical spine following implantation of an artificial cervical disc.  
*Spine.* 2005;30:1949-1954. 61  
 19. Duggal N, Pickett GE, Mitsis DK, et al. Early clinical and  
 biomechanical results following cervical arthroplasty. *Neurosurg*  
*Focus.* 2004;17:62-68. 63  
 20. Pickett GE, Rouleau JP, Duggal N. Kinematic analysis of the  
 cervical spine following implantation of an artificial cervical disc.  
*Spine.* 2005;30:1949-1954. 65  
 21. Reitman CA, Hipp JA, Nguyen L, et al. Changes in segmental  
 intervertebral motion adjacent to cervical arthrodesis: a prospective  
 study. *Spine.* 2004;29:E221-E226. 69  
 22. Wigfield CC, Gill SS, Nelson RJ, et al. The new Frenchay artificial  
 cervical joint: results from a two-year pilot study. *Spine.*  
 2002;27:2446-2452. 71  
 23. Goffin J, Van CF, Van LJ, et al. Intermediate follow-up after  
 treatment of degenerative disc disease with the Bryan cervical disc  
 prosthesis: Single-level and bi-level. *Spine.* 2003;28:2673-2678. 73  
 24. Medtronic Sofamor Danek. Bryan cervical disc image. 2004. 75  
 Medtronic Sofamor Danek USA, Inc. Slide.  
 25. Heller JG, Smucker JD. In Situ Bryan Cervical Disc Post Procedure  
 Images. 2005. Unpublished work. 77